

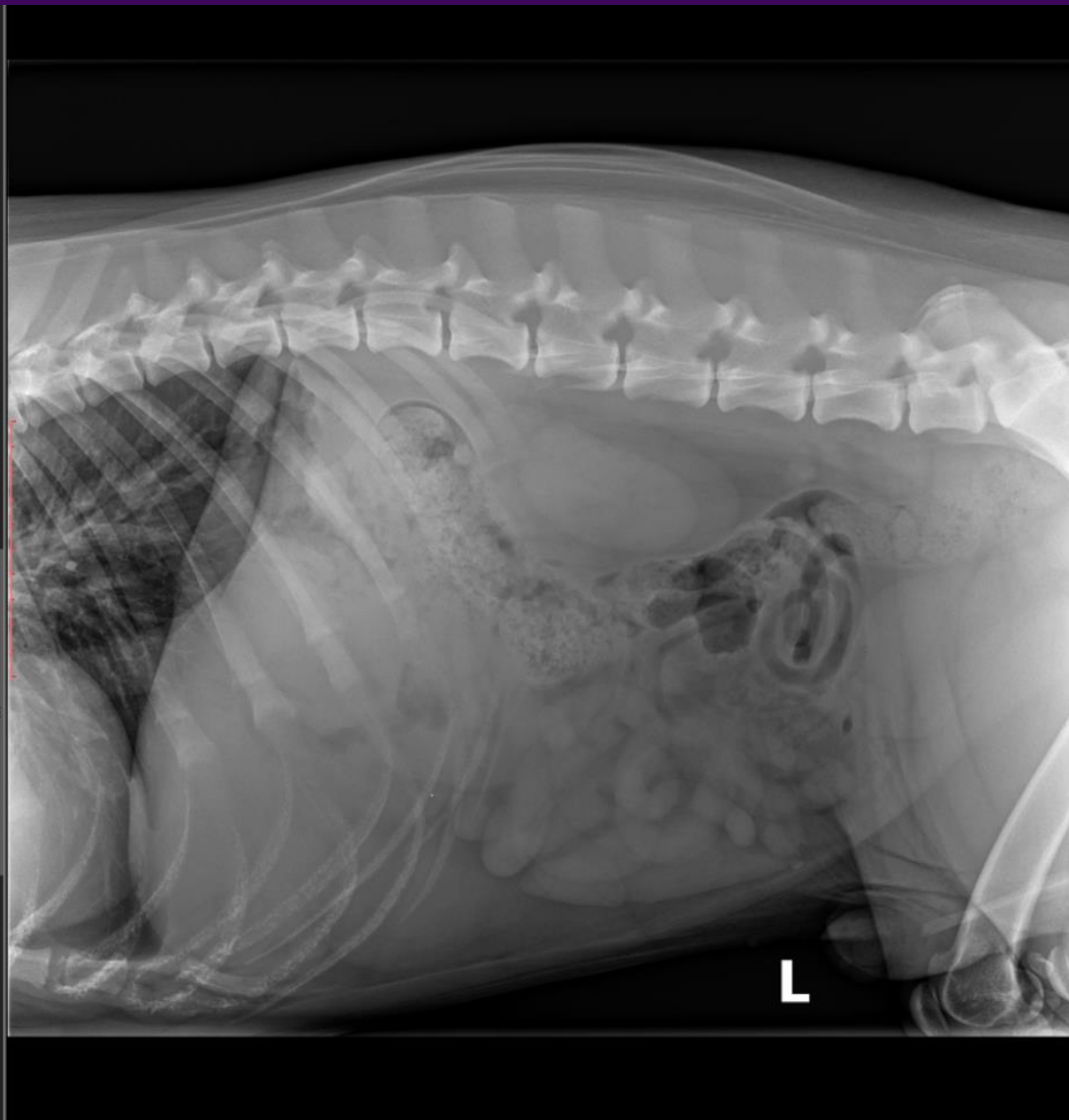
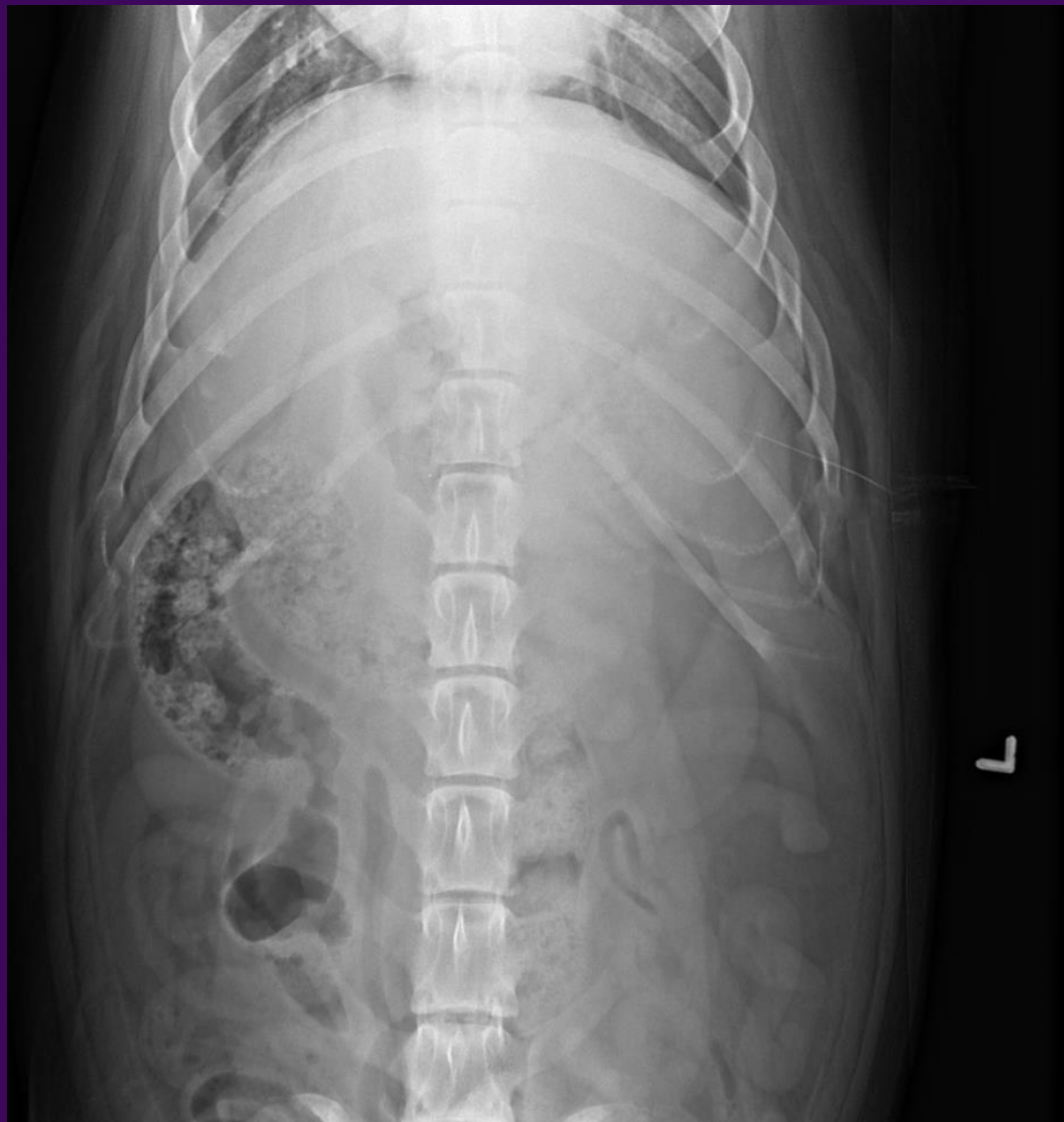Foundations of Urogenital Radiology Case Companion Workbook

Ryan Appleby (he/him/his)

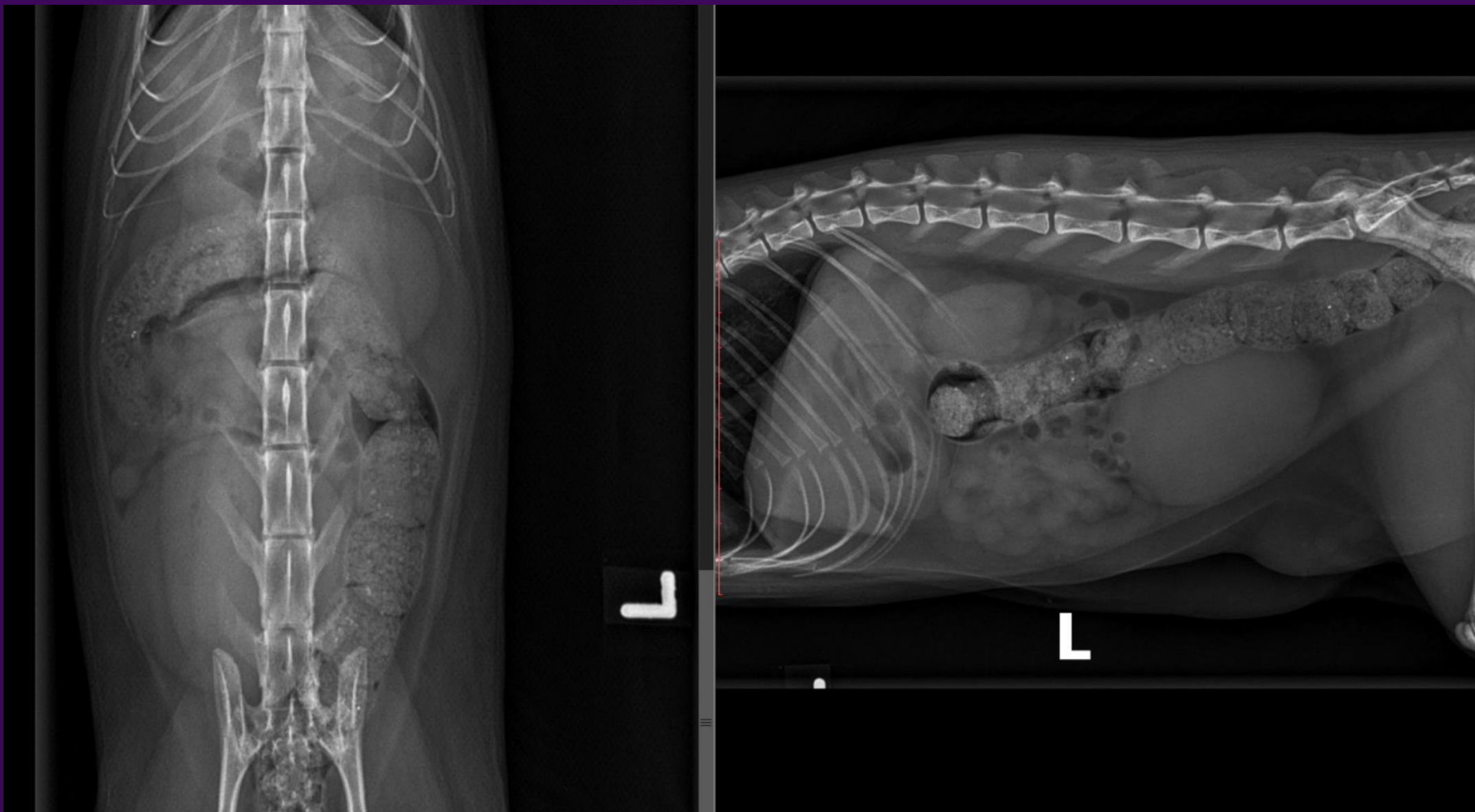Fall 2020



Normal abdomen (dog)



Normal abdomen (cat)



Changes in Renal Roentgen signs

Size, Shape, Margin, Opacity (location, number)

Size

- Enlarged
 - Fluid
 - Hydronephrotic
 - Cystic
 - Perirenal fluid
 - Solid
 - Neoplasia
 - Hematoma
 - Mixed
 - Abscess
 - Hemorrhage + Hematoma
- Small
 - Congenital
 - Acquired

Shape

- Round
- Oval
- Lobulated

Opacity

- Mineralized
 - Linear
 - Rounded

Margin

- Smooth
- Irregular
 - Indentation
 - Scar from infarct
 - Elevation/bulge
 - Tissue proliferation
 - Cyst

Differential Diagnoses based on size and margin:

Mildly enlarged kidney, smooth margin

Bilateral

- Acute renal injury
- Acute pyelonephritis
- Congenital portosystemic shunt
- Amyloidosis
- Acromegaly

Unilateral

- Compensatory hypertrophy
- Renal neoplasia (except lymphoma)
- Subcapsular abscess/hemorrhage

Enlarged kidney, irregular margin

Bilateral

- Metastatic neoplasia
- Polycystic kidney disease
- Feline infectious peritonitis

Unilateral

- Primary renal neoplasia
- Metastatic neoplasia
- Renal abscess
- Renal hematoma
- Renal cysts
- Renal granuloma

Markedly enlarged kidney, smooth margin

Bilateral

- Hydronephrosis
- Renal lymphoma
- Feline infectious peritonitis
- Feline perinephric pseudocysts

Unilateral

- Hydronephrosis
- Renal tumor
- Subcapsular hematoma or abscess
- Perinephric pseudocyst

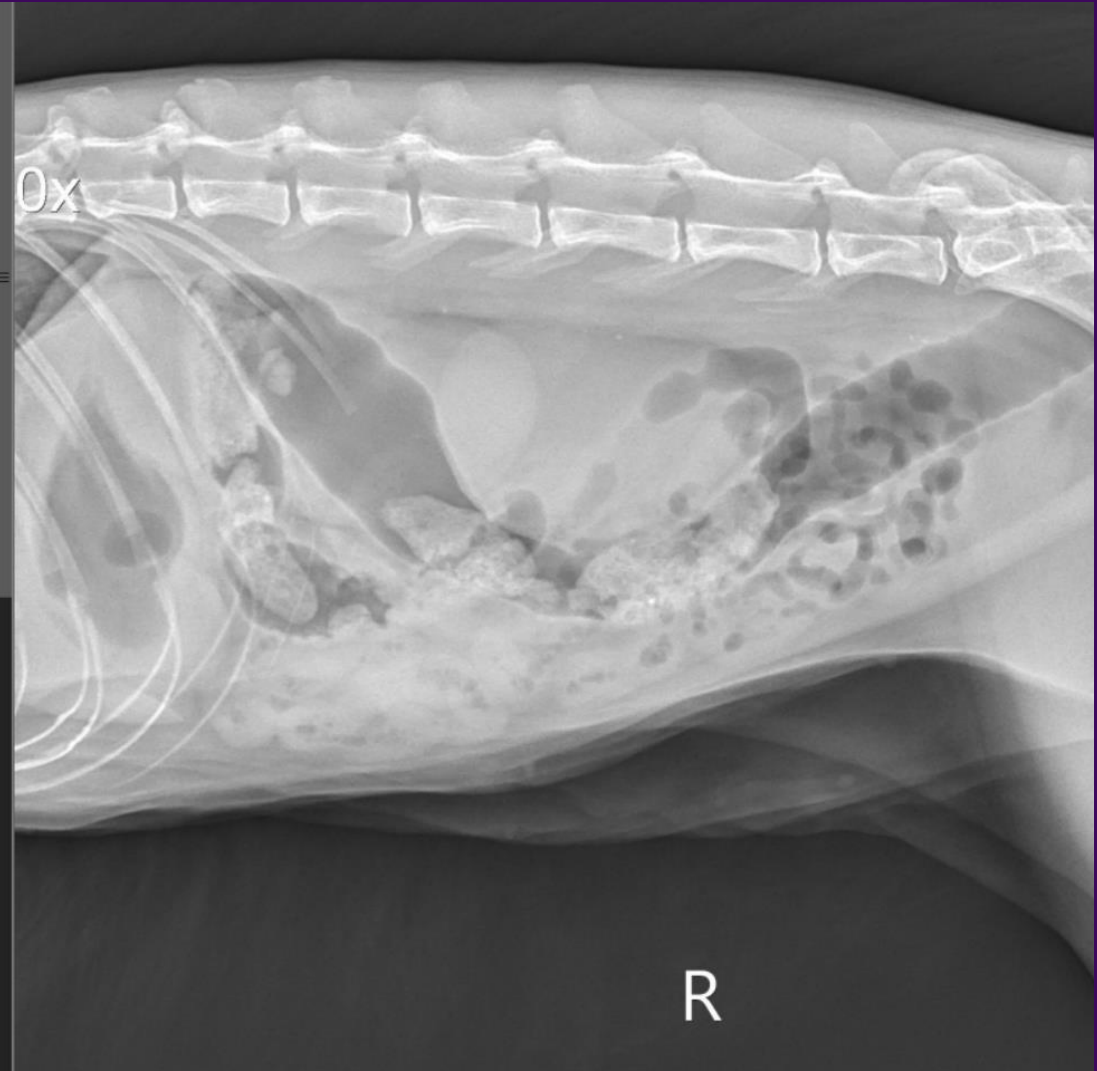
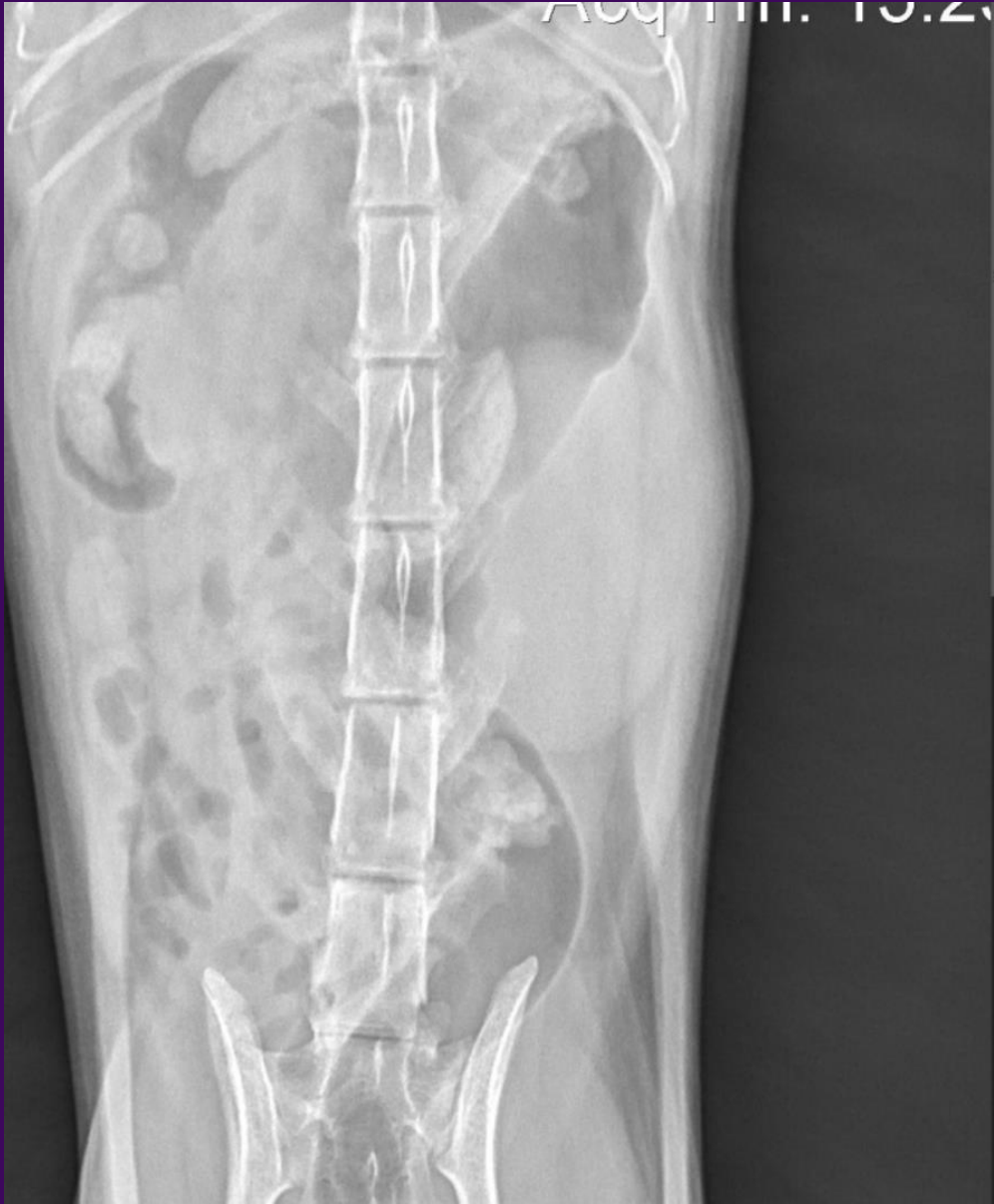Small kidney, smooth or irregular margin

Bilateral

- Chronic renal disease
- Developmental hypoplasia or dysplasia

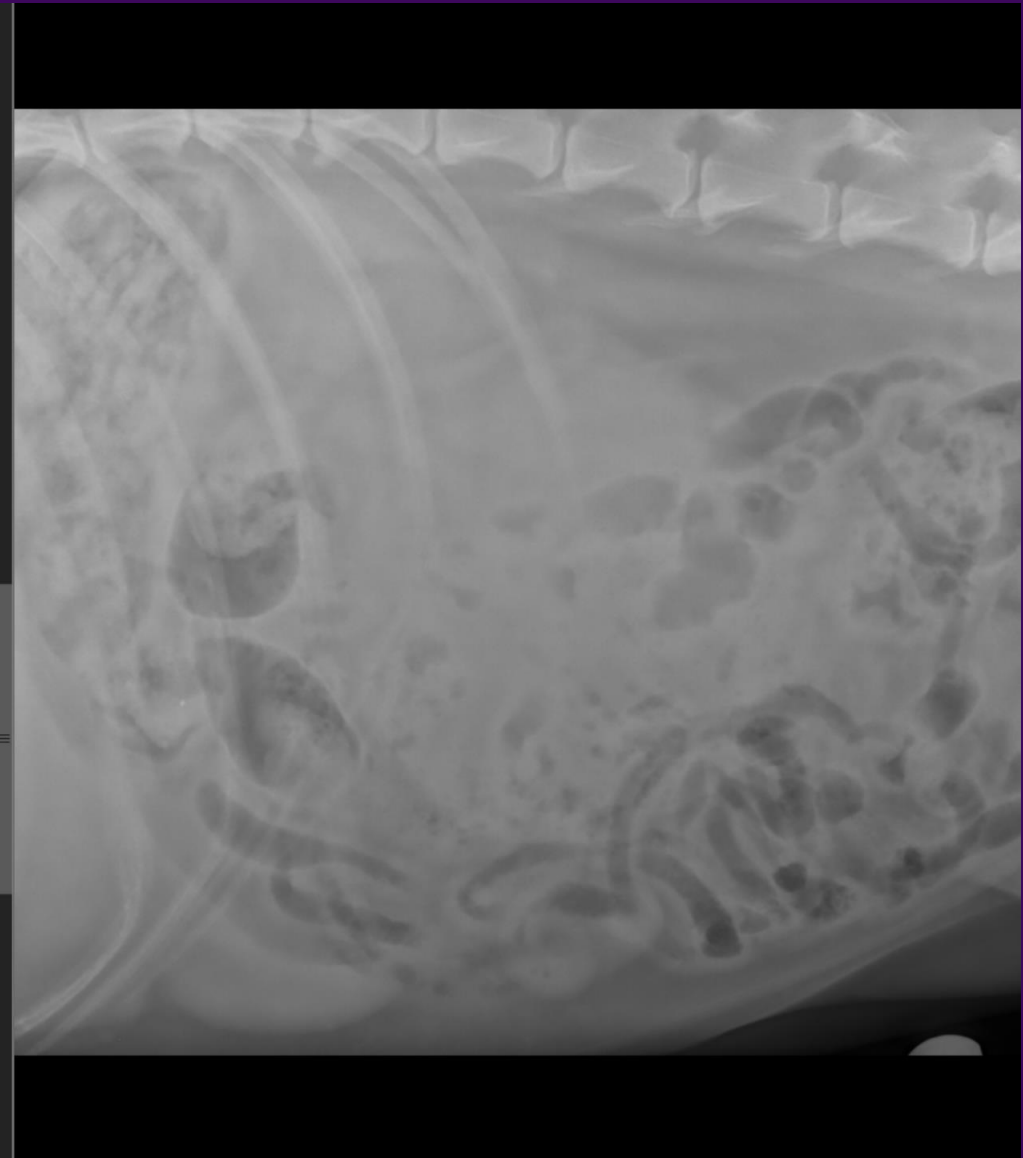
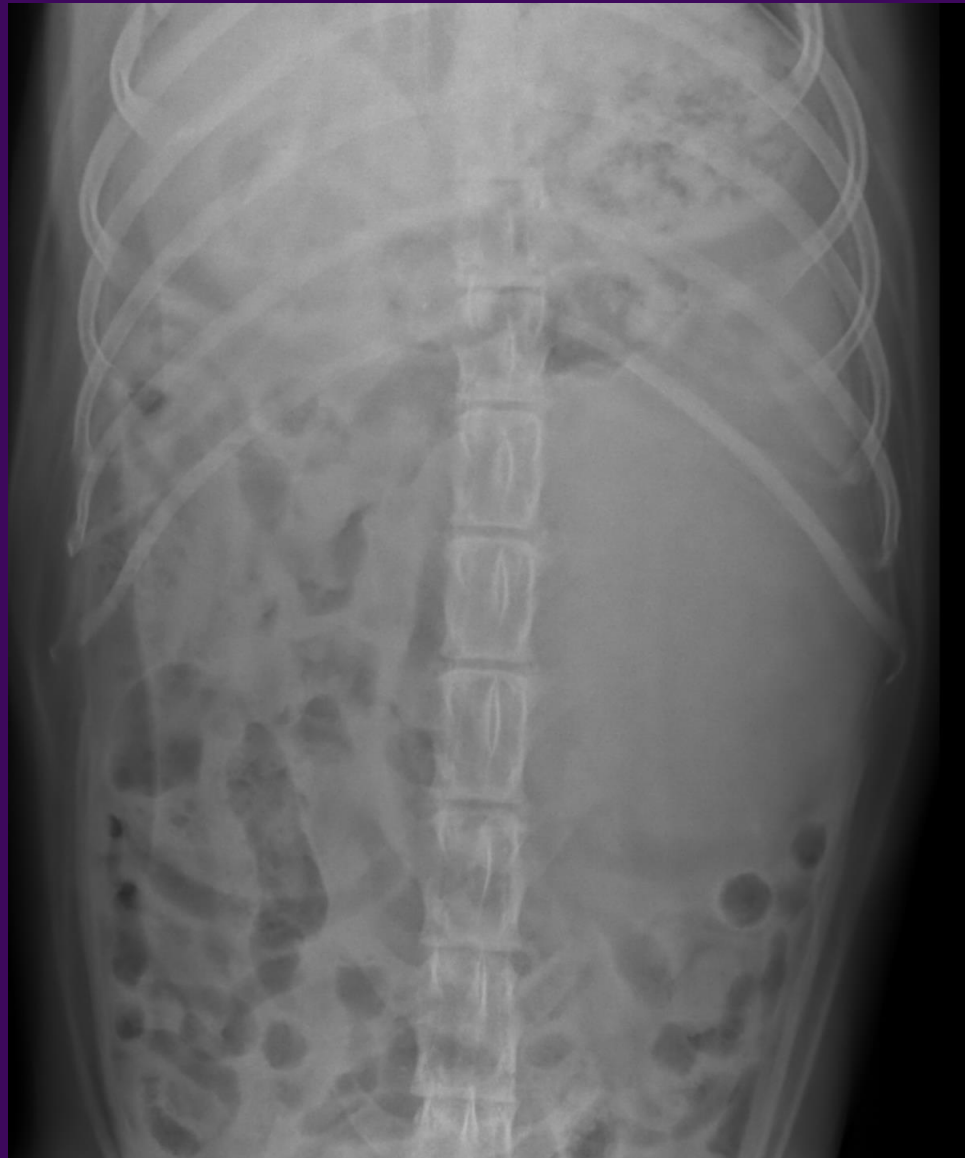Unilateral

- Chronic renal disease
- Atrophy secondary to obstruction

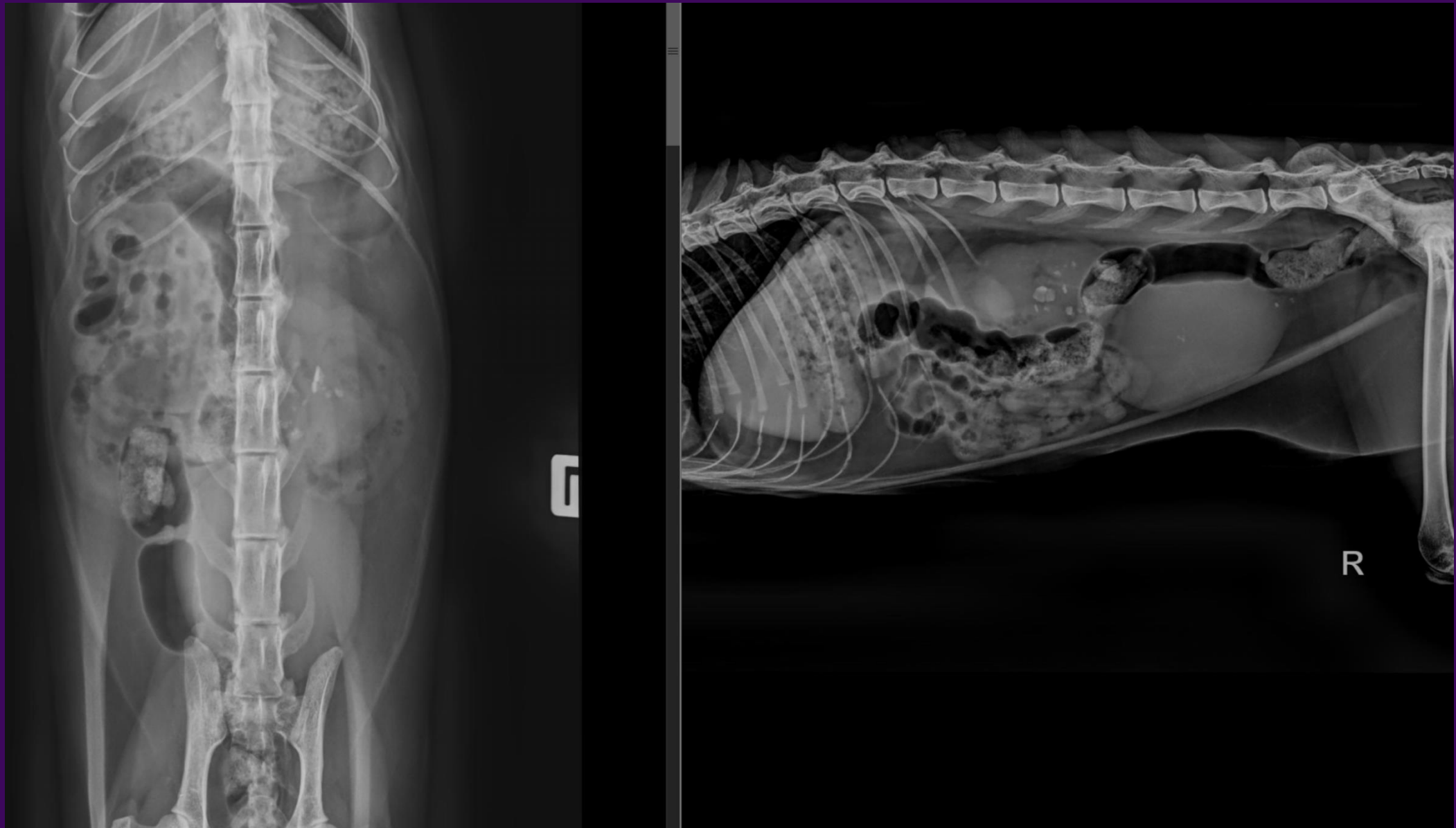


Renomegaly – feline
Ureteral obstruction

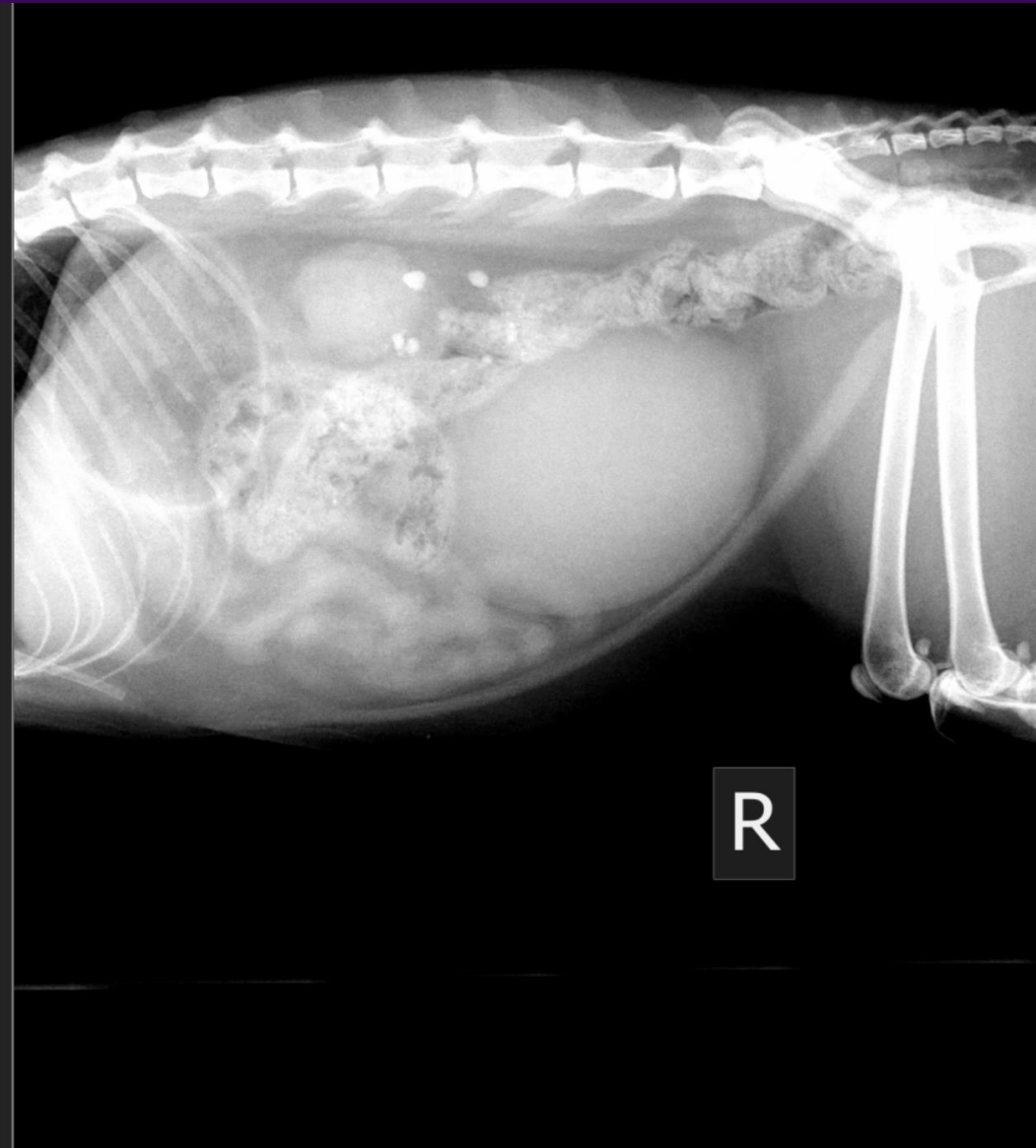
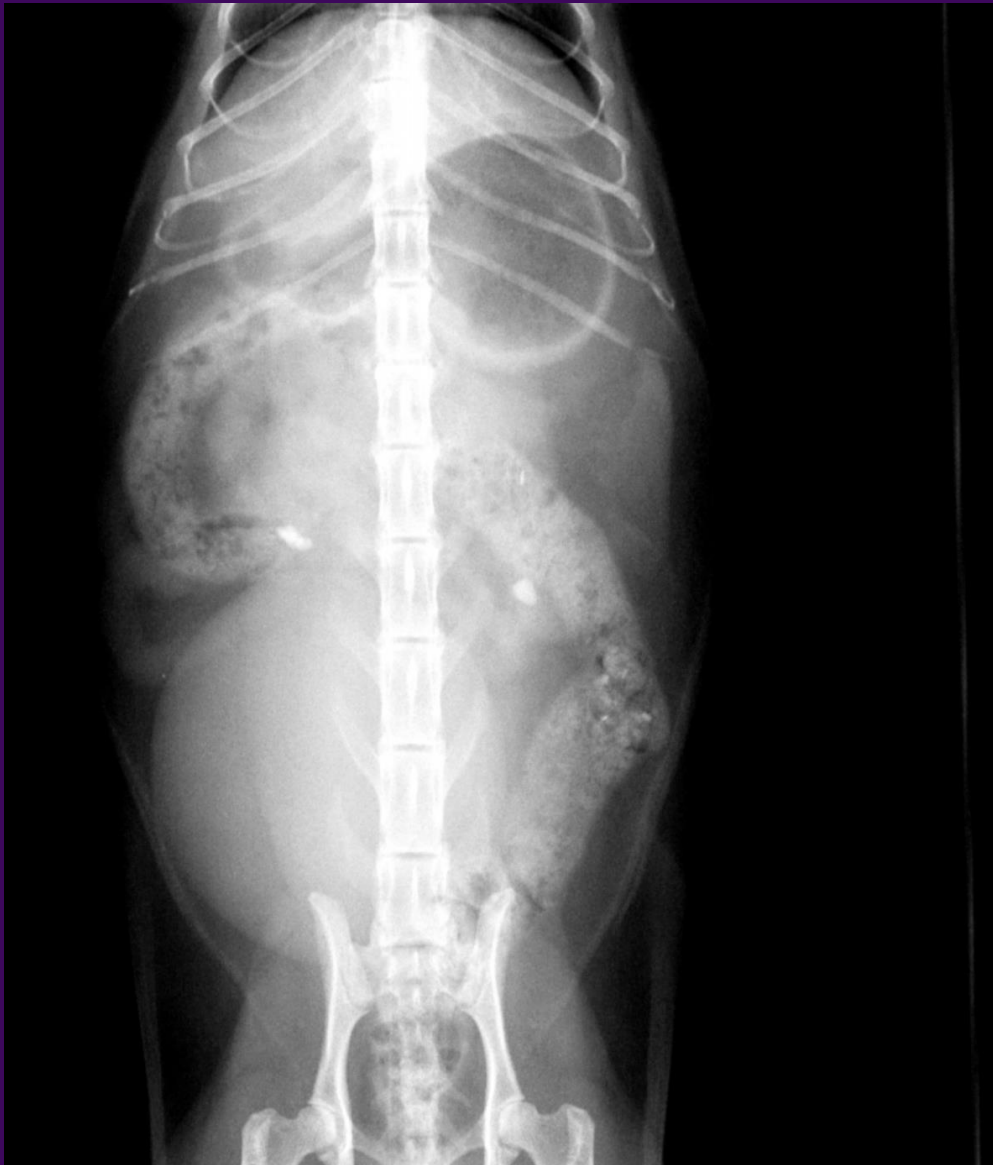Left Renomegaly – renal mass



Renal asymmetry, chronic kidney disease

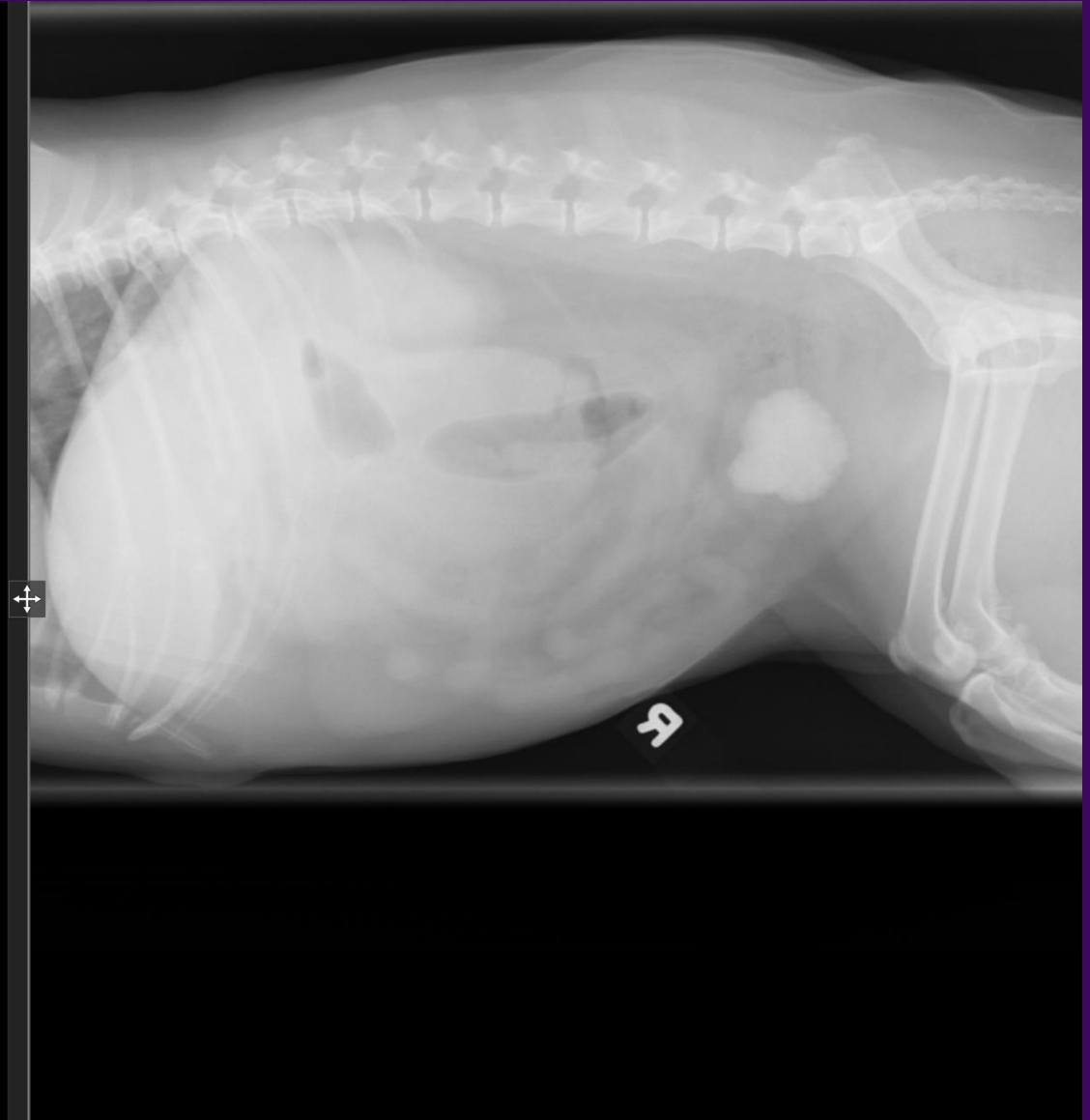
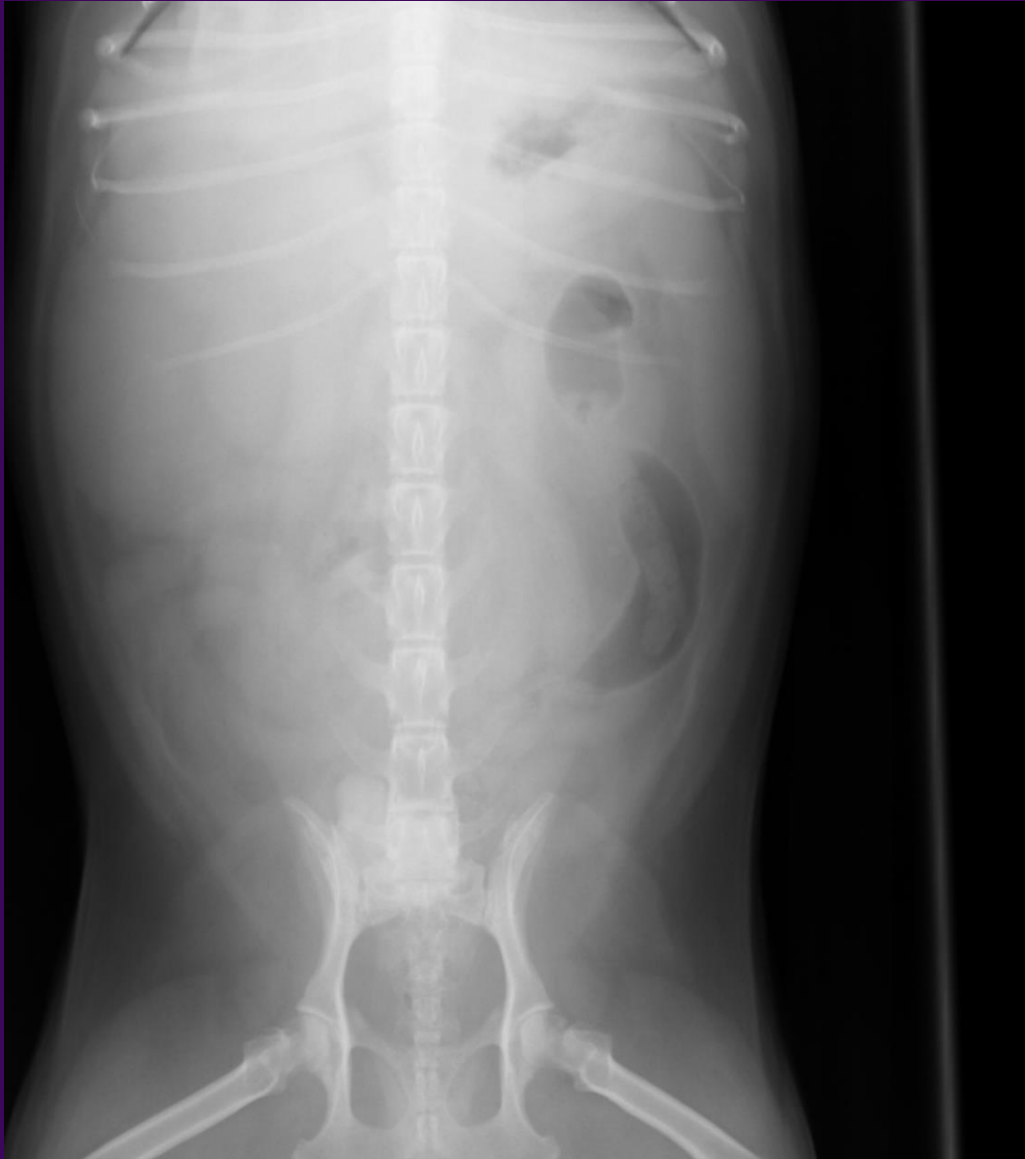

Chronic kidney disease (CKD)

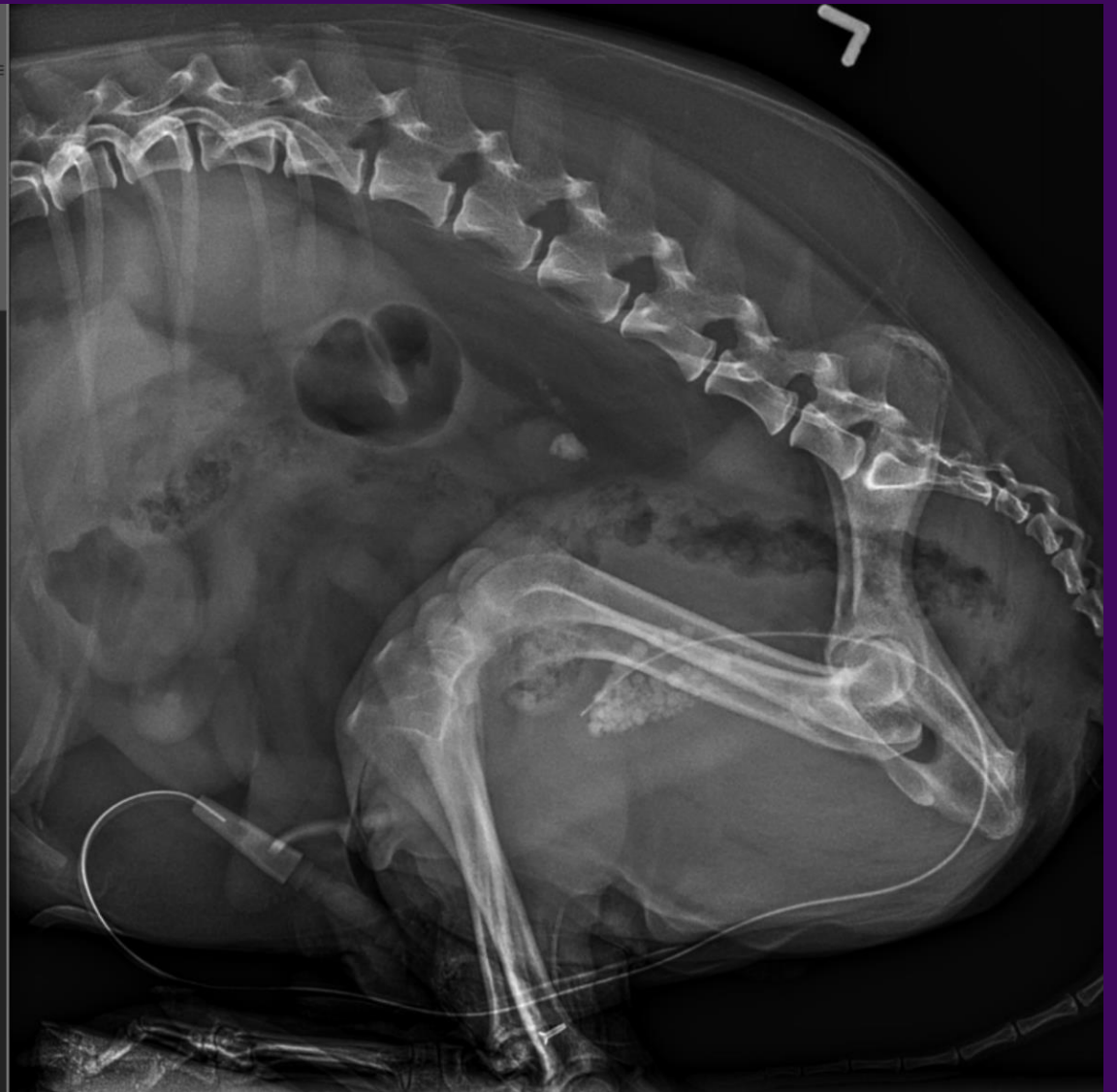
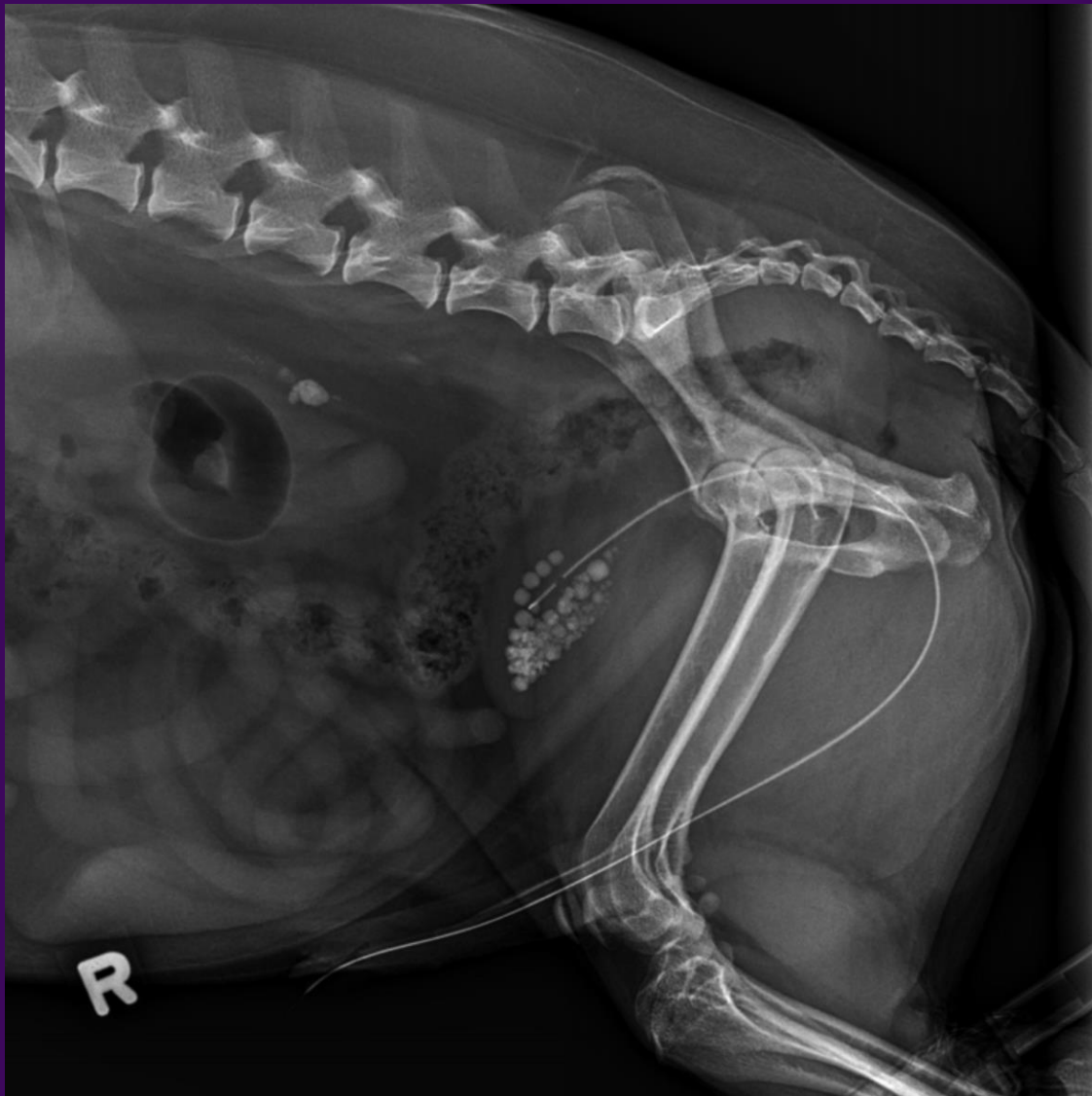
Cystolith

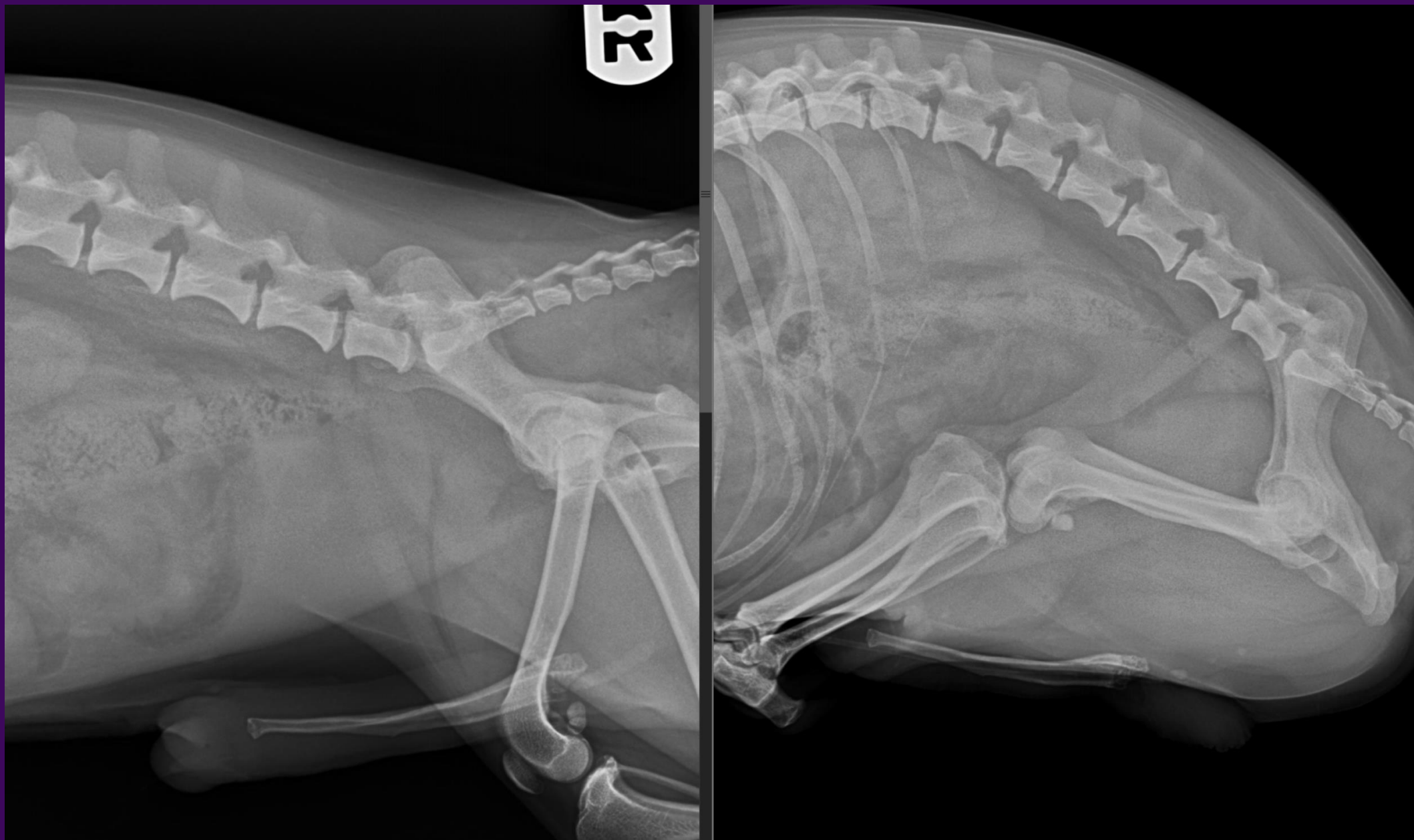
Right cranial abdominal mass (hepatic mass)



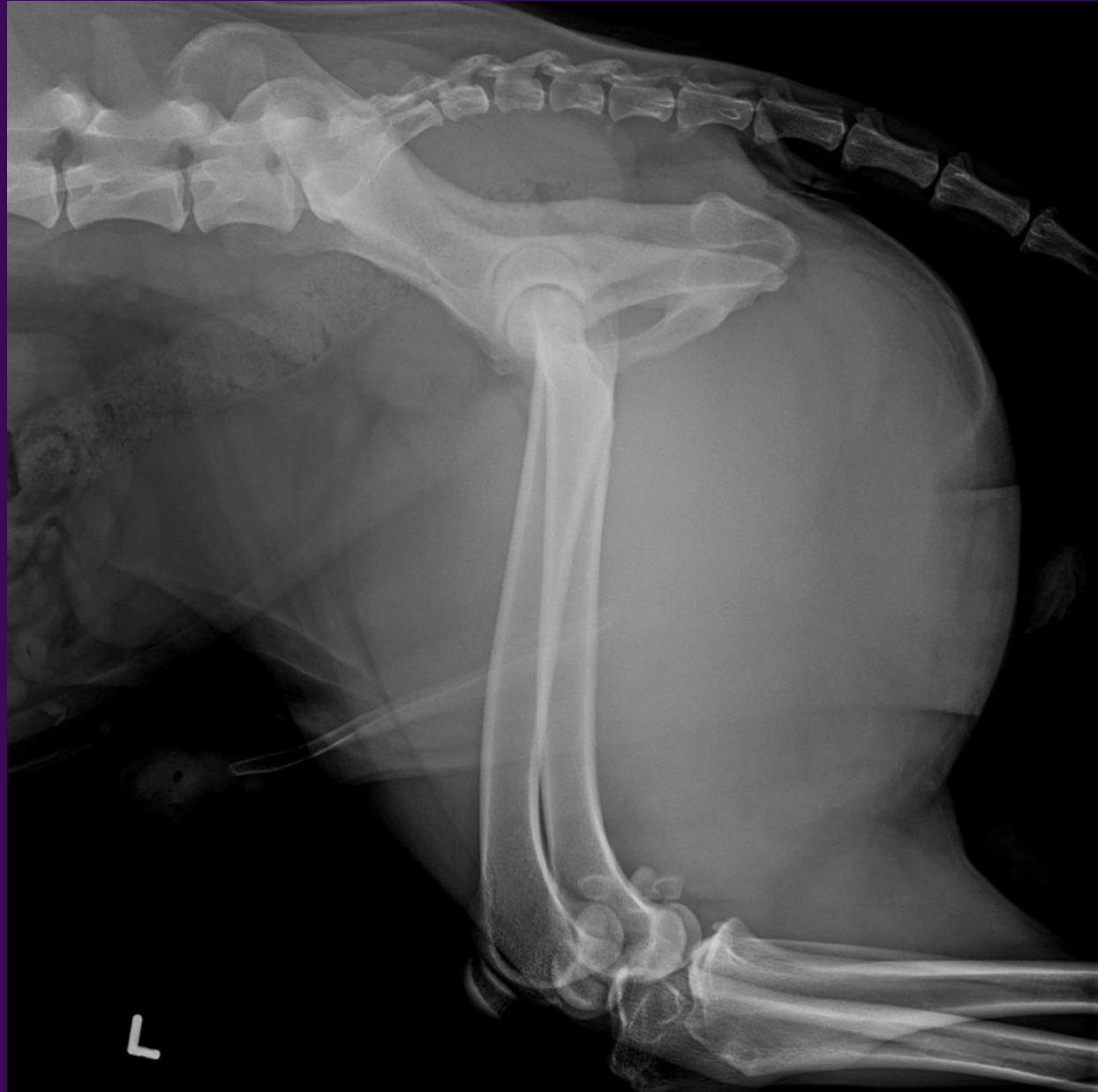
Cystoliths, ureterolith, urinary catheter



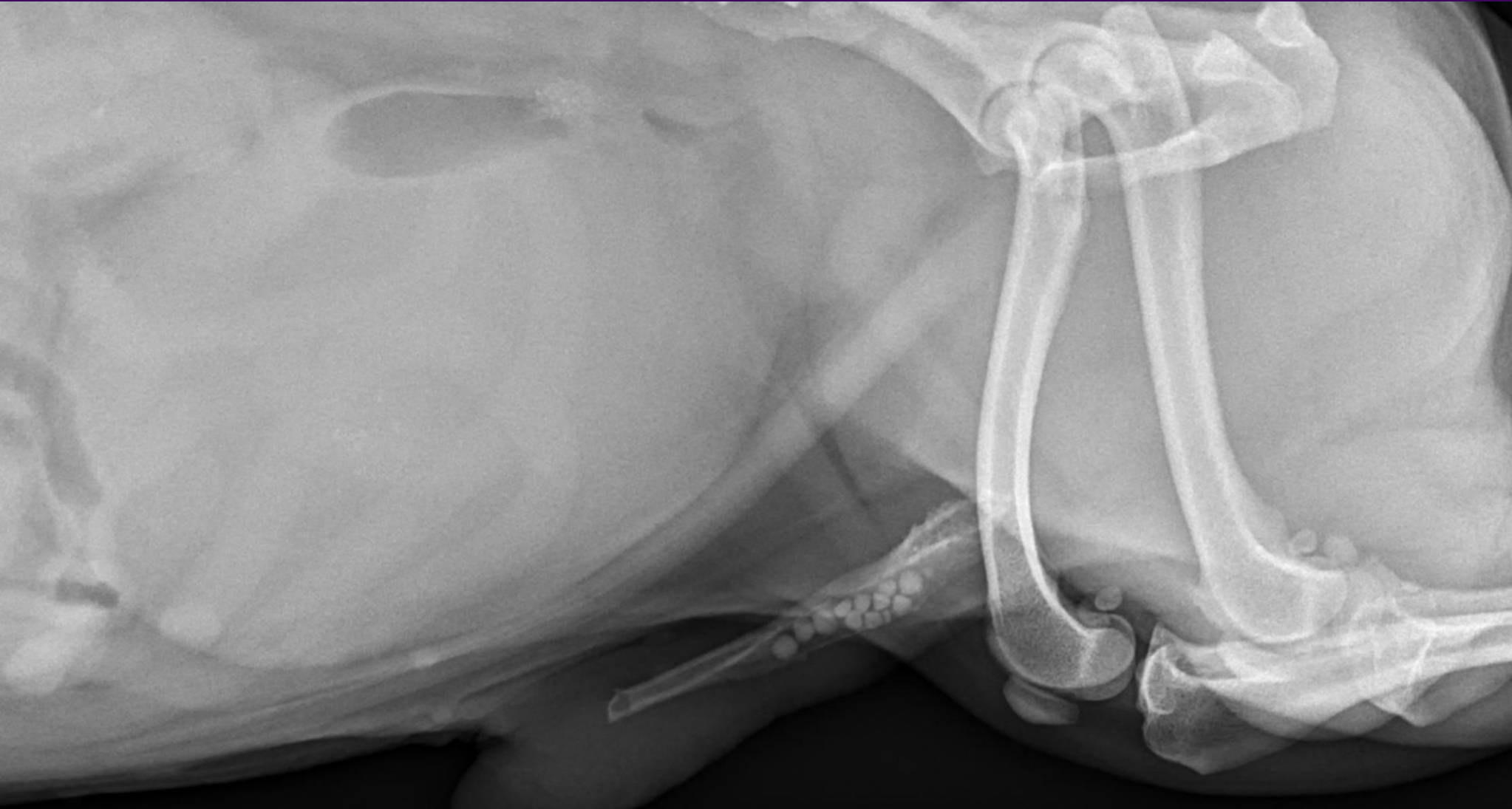
Flexed leg lateral for urethral evaluation



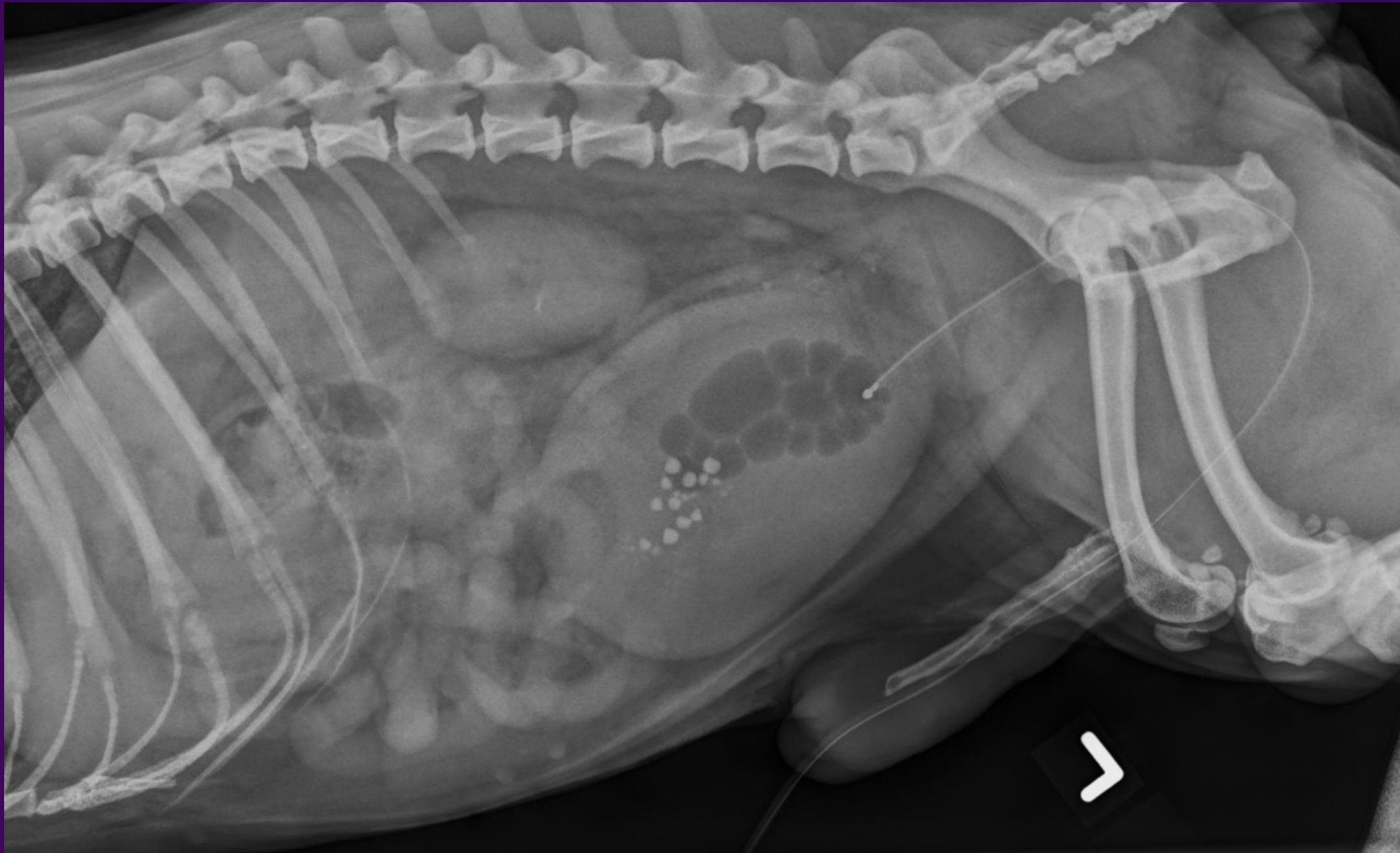
Prostatomegaly



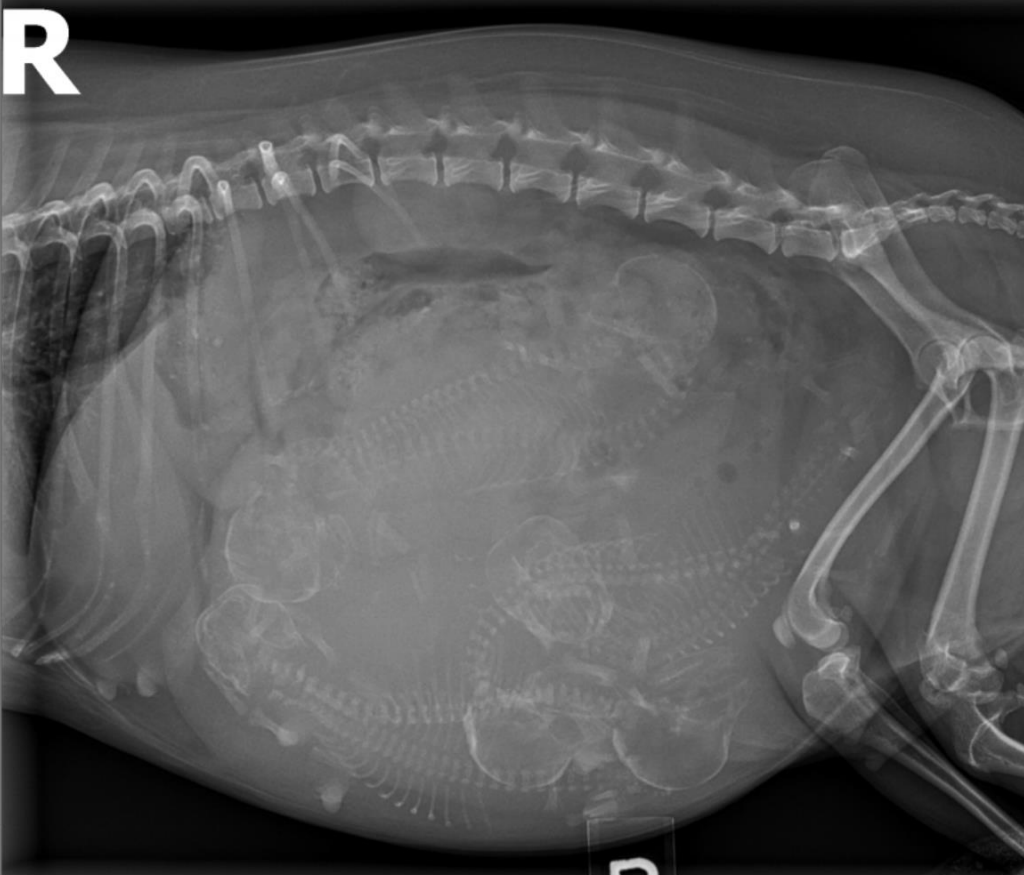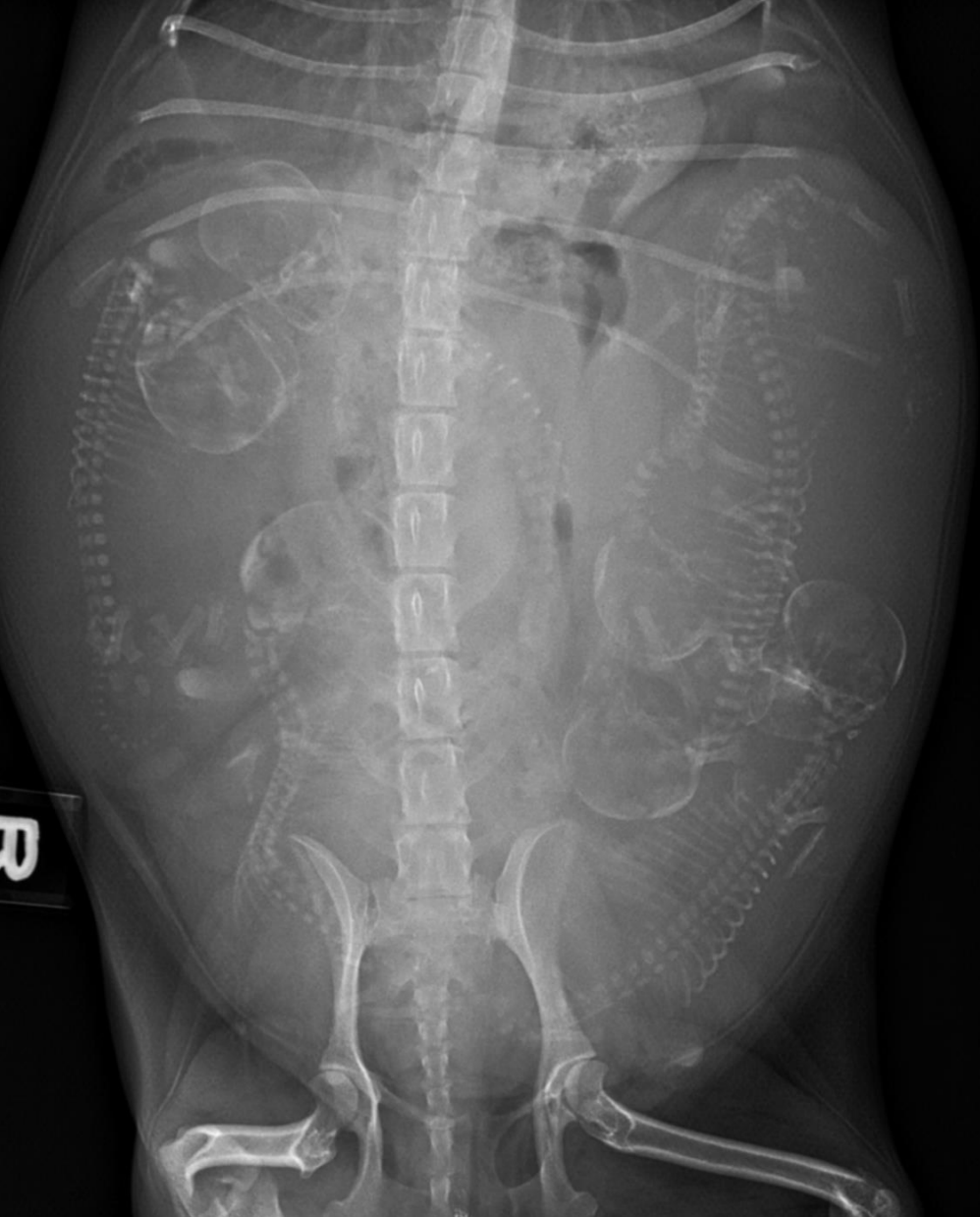Prostatomegaly, urethroliths



Retropulsed urethroliths and prostatomegaly



Normal pregnancy



Pyometra

